



## PATIENT

Birdie Moore

## SPECIES

Canine

## BREED

Chihuahua

## SEX

Female Spayed

## AGE

12 years

## WEIGHT

13lbs

## INTERPRETED BY

Maggie Machen Lamy,  
DVM, DACVIM  
(Cardiology)

## IMAGING PERFORMED BY

Meg Schneck

## HOSPITAL NAME

Willamette Veterinary  
Hospital

## REFERRING VET

Dr. Harmon

## INVOICE

25195

## DATE

7/7/22

## PRESENTING CLINICAL SIGNS

History: History of heart disease since 2019. Chronic progressive cough past 6 mo. Became dyspneic today and seen and treated at rDVM prior to referral for overnight hosp and continued oxygen therapy. Labs taken after stabilization (O2 therapy, IV furosemide, IV butorphanol) and furosemide. Furosemide given over the day for total of 9.8 mg/kg Butorphanol 0.2 mg/kg TFAST noted B lines, no pleural or pericardial effusion. Patient transferred and O2 continued, tachypnea continued, grade 5/6 systolic murmur, crackles present at ~6pm, EPOC: mild azotemia (creatinine 1.7, BUN28), elevated lactate (3.29), hypernatremia (156), mild hypocalcemia (1.1), Hct 65%.  
-CXR report (7/6/22): Showed cardiomegaly with CHF +/- pneumonia.  
-Despite treatment of CHF tachypnea worsened and repeat radiographs were taken.  
CXR report (7/7/22): Significant pulmonary disease noted obscuring cardiac silhouette. Concern for CHF again +/- bronchopneumonia

## ECHOCARDIOGRAM FINDINGS

2D, m-mode and Doppler imaging are available. Diffuse thickening of mitral valve leaflets (anterior > posterior) with minimal prolapse into the left atrial lumen. Severe eccentric mitral regurgitation with severe left atrial dilation. Mild LV dilation with hyperdynamic myocardial function. The tricuspid valve appears normal with trace tricuspid regurgitation. Velocity consistent with mild pulmonary hypertension. Mild right heart enlargement. The pulmonic and aortic valves are normal in morphology and mobility. Normal pulmonic and aortic outflow velocities. No pulmonic or aortic insufficiency. No pericardial or pleural effusion noted. No cardiac tumors observed.

## CARDIAC CHART

CANINE CARDIAC PARAMETERS	MR VMAX (m/s)	TR VMAX (m/s)	LA/AO (Boon method)	LA/AO (Heart Base; Swe)	FS (%)	EF (%)	EPSS (cm)
NORMAL PARAMETER	4.5-5.5	<2.7	1.3	<1.6	28-40	40-100	<0.6
PATIENT	NM	2.8	NM	2.5	54	92	NM
CANINE CARDIAC PARAMETERS	HR (BPM)	AV VMAX (m/s)	PV MAX (m/s)	BODY WEIGHT (kg)	LA 2D short axis Base view (cm)	LVIDd Avg; 2D and m-mode short axis (cm)	LVIDs Avg; 2D and m-mode short axis (cm)
NORMAL PARAMETER	50-100	0.7-1.7	0.7-1.6	BELOW	BELOW	BELOW	BELOW
PATIENT	NM	0.39	0.6	5.9	2.6	3.1	1.4
*Normal chamber parameters expressed as a mean value (SD)				3	1.27 (5.3)	2.46 (2.46)	1.36 (5.5)
<b>BODY WEIGHT DEPENDENT PARAMETERS</b>				5	1.40 (4.5)	2.74 (5.2)	1.60 (4.7)
<i>*Note: All measurements based upon multi-modal images and methods. An average value is reported.</i>				10	1.50 (3.8)	3.27 (3.5)	2.06 (3.1)
				15	1.83 (2.0)	3.71 (2.4)	2.43 (2.1)
				20	2.02 (1.9)	4.14 (2.2)	2.80 (2.0)
				25	2.18 (2.4)	4.48 (2.9)	3.10 (2.5)
				30	2.33 (3.3)	4.83 (3.9)	3.39 (3.4)
				35	2.48 (4.3)	5.17 (5.0)	3.69 (4.5)
				40	2.62 (5.2)	5.48 (6.1)	3.96 (5.4)
				50	2.88 (7.1)	6.07 (8.3)	4.46 (7.4)

Adapted from June Boon, Veterinary Echocardiography, 1998  
Rishniw M and Hollis NE, J Vet Intern Med 2000; 14:429-435  
Hansson et al, Vet Rad and Ultrasound 2002  
Bonagura et al. Echocardiography: principles of interpretation, Vet Clin North Am 15:1177, 1995



**PATIENT**

Birdie Moore

**SPECIES**

Canine

**BREED**

Chihuahua

**SEX**

Female Spayed

**AGE**

12 years

**WEIGHT**

13lbs

**INTERPRETED BY**

Maggie Machen Lamy,  
DVM, DACVIM  
(Cardiology)

**IMAGING PERFORMED BY**

Meg Schneck

**HOSPITAL NAME**

Willamette Veterinary  
Hospital

**REFERRING VET**

Dr. Harmon

**INVOICE**

25195

**DATE**

7/7/22

**INTERPRETATION OF THE FINDINGS & FURTHER RECOMMENDATIONS**

Chronic degenerative valve disease causing severe mitral and trace regurgitation. Severe left atrial enlargement indicates the risk for spontaneous congestive heart failure is elevated. Mild pulmonary hypertension is noted. No additional issues are identified.

The described respiratory signs are likely multi-factorial in origin, given the radiographic evaluation and lack of response to Lasix. My guess is there is a combination of respiratory and cardiac disease that is leading to recent acute decompensation. While severe structural disease is seen here, the diagnosis of CHF versus respiratory compromise versus a combination of the two is a Radiographic determination (ie a patient can have severe subclinical cardiac disease with primary respiratory compromise alone). A lack of response to Lasix would support a multifactorial issue. Going forward, highly recommend full cardiac support, including Lasix therapy with coverage for primary respiratory issues with a broad-spectrum antibiotic therapy. No significant pulmonary hypertension is noted at this time; however, this may develop in the future or may be under-estimated here. If the lack of response to therapy persists, a trial of sildenafil seems reasonable in this case. Hydrocodone can be utilized for quality of life.

Monitoring of sleeping breathing rates in the future will be paramount to determine the origin of any future cough. The average survival of canine patients with active pulmonary edema is 8-9 months on medications, however they generally are able to maintain a good quality of life for that period. Patient will always be at risk for recurrent CHF, development of arrhythmias/LA tear, syncope and/or sudden death in the future. Monitoring of renal values is recommended lifelong.

Omega fatty acid supplementation and mild salt restriction may also be of some long-term benefit. Monitor for development of a worsening cough, labored breathing, exercise intolerance or collapse episodes.

Elective anesthesia, fluid or steroid therapy are not recommended.

**PLAN**

Screening BP is recommended. Continued hospitalization for oxygen support until stable, continuing injectable Lasix, oral Pimobendan, and broad spectrum antibiotic (Baytril or similar). If a lack of response to medications persists, a trial of Sildenafil can be utilized, 1-2mg/kg PO q8h. Discharge on the following:

Administer Pimobendan 0.3mg/kg PO q12h. Administer Lasix 1-2mg/kg PO q12h. Administer spironolactone 1-2mg/kg PO q12h. Continue broad-spectrum antibiotic, such as Baytril for at least 2 weeks+/- Hydrocodone (0.2-0.4mg/kg PO up to q4-6 hours PRN) as needed. If Sildenafil is instituted and is beneficial, this should also be continued.

Recommend recheck CXR in 1-2 weeks to reestablish a baseline.

A renal panel and BP are recommended in 10-14 days, then every 3-4 months on diuretics to ensure tolerance of medications. If doing well at that time and BP >130mmHg, institute ACEI 0.5mg/kg PO q12h.

A recheck echocardiogram is recommended in 6 months to screen for progression, sooner if clinical signs arise/persist.



**PATIENT**

Birdie Moore

**SPECIES**

Canine

**BREED**

Chihuahua

**SEX**

Female Spayed

**AGE**

12 years

**WEIGHT**

13lbs

**INTERPRETED BY**

Maggie Machen Lamy,  
DVM, DACVIM  
(Cardiology)

**IMAGING  
PERFORMED BY**

Meg Schneck

**HOSPITAL NAME**

Willamette Veterinary  
Hospital

**REFERRING VET**

Dr. Harmon

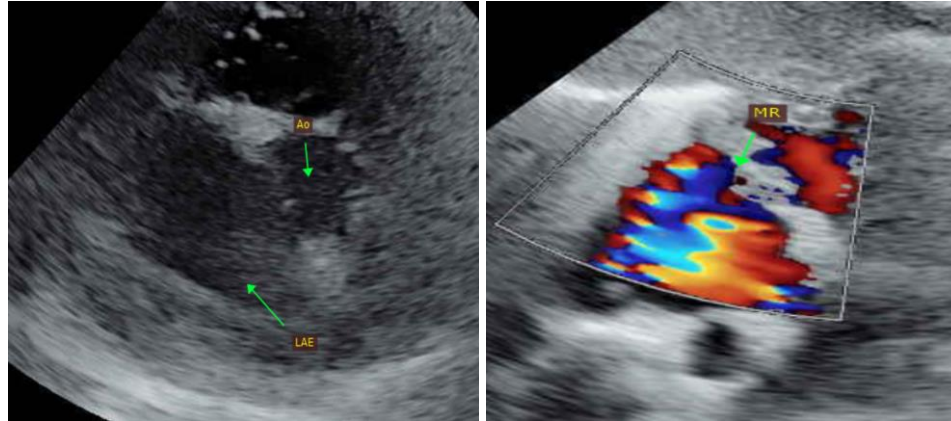
**INVOICE**

25195

**DATE**

7/7/22

**IMAGES**



The information and recommendations provided are based on the images presented by the referring veterinarian. No evaluation can be communicated regarding pathology that was not visible in the image/video clips provided.

Thank you for this referral. This report was generated using transcription software, and minor dictation errors may be present. If the clinical or image interpretation does not parallel your findings or if I can be of any further assistance, please contact me.

**Maggie Machen Lamy, DVM**  
Diplomate of the American College of Veterinary Internal Medicine (Cardiology)  
info@sonopath.com